

Supplement to November 2002

**skin**  
AGING



HARNESSING **LIGHT**  
TO TREAT **STRETCH MARKS**  
AND OTHER HYPOPIGMENTED SCARS



HMP COMMUNICATIONS

Supported by an educational grant from Lumenis Inc.

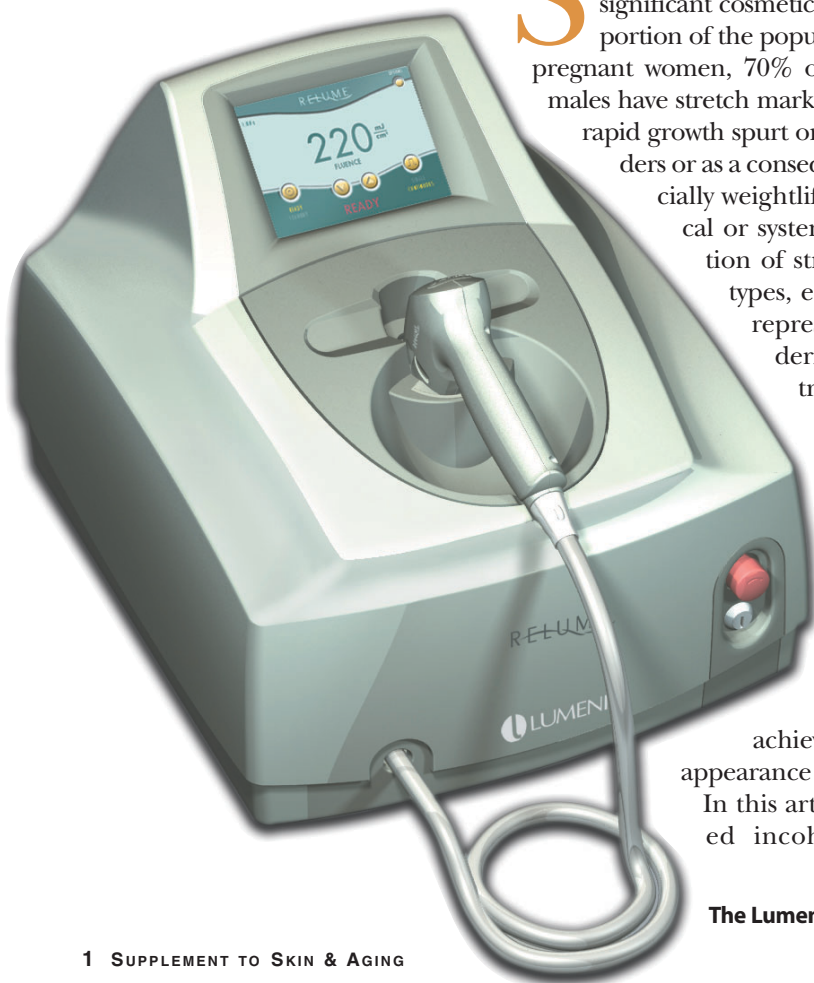
# HARNESSING **LIGHT**

## TO TREAT **STRETCH MARKS** AND OTHER HYPOPIGMENTED SCARS

**New research highlights successes in repigmenting mature stretch marks and hypopigmented scars.**

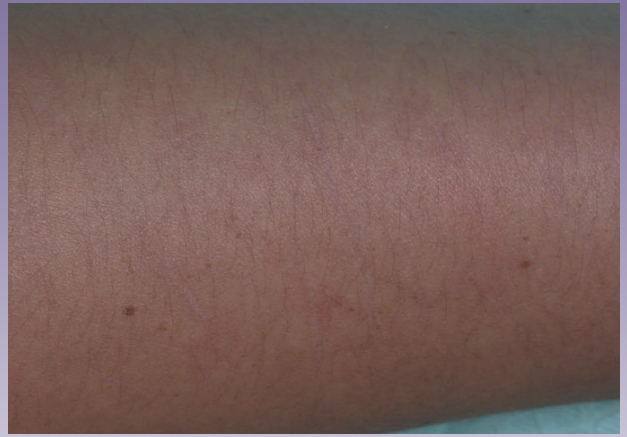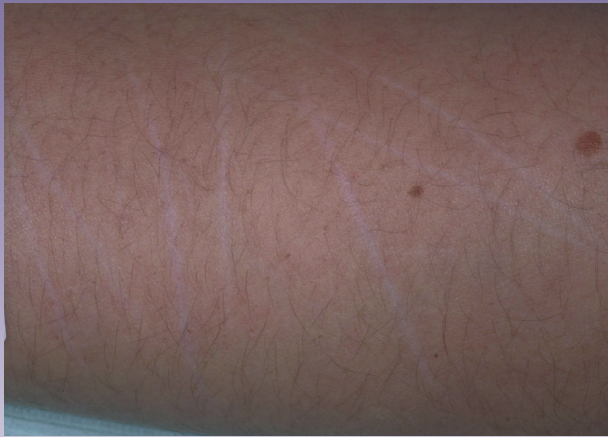**S**tretch marks, or striae distensae, occur very commonly and create significant cosmetic skin disfigurement. These marks affect a large portion of the population. It's reported that approximately 90% of pregnant women, 70% of adolescent females and 40% of adolescent males have stretch marks.<sup>1</sup> In men, striae typically occur as a result of a rapid growth spurt or weight gain at puberty, from endocrine disorders or as a consequence of participation in certain sports, especially weightlifting. Excessive or chronic use of potent topical or systemic corticosteroids also promotes the formation of striae.<sup>2</sup> Although frequently classified into two types, early (red) and mature (white or alba), striae represent linear dermal scars accompanied by epidermal atrophy. While the use of lasers or light treatments to diminish the appearance of striae has been reported by a number of sources, controlled clinical studies are rare. New evidence suggests that targeted light therapy may have a significant benefit. We believe that the hypopigmented component of striae can be safely treated with targeted 290 nm to 400 nm ultraviolet (UV) light. The improvement may be enhanced in combination with other therapeutic modalities that aid in collagen remodeling in order to achieve safe and effective improvement in the appearance of striae distensae.

In this article, we'll focus on the use of a novel targeted incoherent UV light source, the ReLume™



**The Lumenis ReLume Repigmentation Phototherapy System**





**Hypopigmented traumatic scar before (at left) and after eight ReLume treatments (at right).**

*Photos courtesy of Dr. Roy Geronemus & Dr. Macrene Alexiades-Armenakas*

Repigmentation Phototherapy System (Lumenis, Inc., Santa Clara, CA), for treating mature striae and other hypopigmented non-linear dermal scars. First, we'll review the etiology of striae and discuss other treatments that have been employed to diminish their appearance.

### ETIOLOGY

The factors that lead to the development of striae are poorly understood. Early changes include inflammation and capillary dilation. It is believed that stress shattering of the collagen framework initiates an inflammatory response that ultimately results in a thin and flattened epidermis with loss of the rete ridges and loss of melanocytes. Elastic stains show breakage and retraction of the elastic fibers in the reticular

dermis.<sup>3,4</sup> Other dermal changes include thin, densely packed collagen bundles arranged in a parallel array horizontal to the epidermis at the level of the papillary dermis. Extracellular matrix alterations that mediate the clinical appearance of stretch marks remain poorly understood. With time, striae assume their typical white atrophic appearance with the long axis aligned parallel to the lines of skin tension. According to McDaniel, this development is very similar to that of surgical wound healing.<sup>5</sup>

### A REVIEW OF TOPICAL TREATMENTS FOR STRIAE

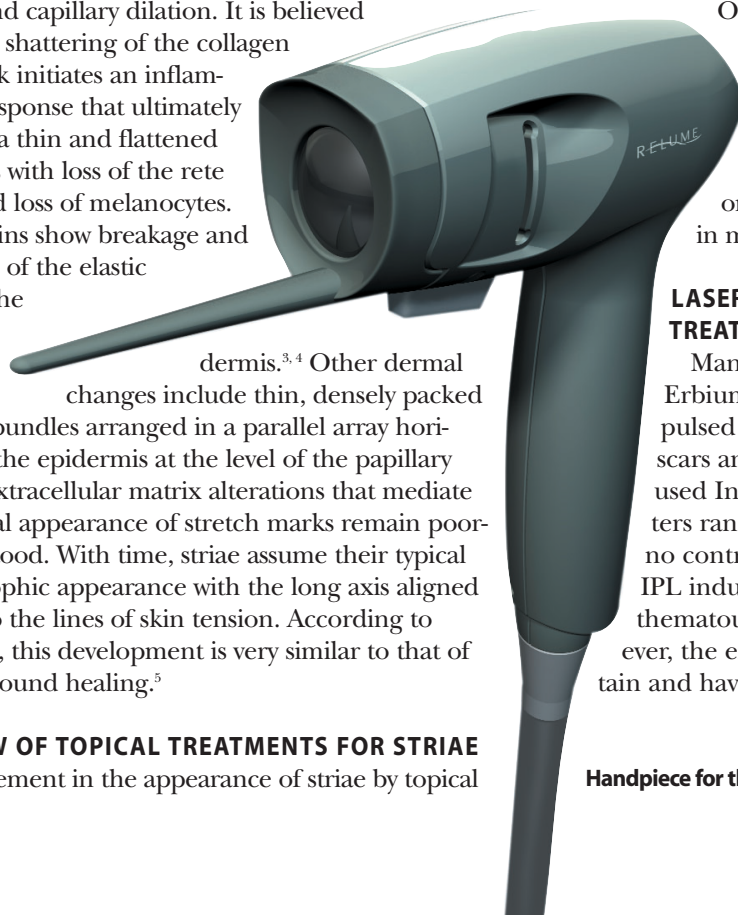
Improvement in the appearance of striae by topical

agents has been aggressively sought for many years. Topical tretinoin in a 0.1% concentration has been shown to be effective for striae rubra or early, red, inflammatory stretch marks.<sup>6</sup> However, it failed to significantly improve mature stretch marks (striae alba).<sup>7</sup> Whether the improvement of striae rubra leads to a diminution in the final appearance of the striae remains unknown. Recent data suggests that the application of 20% glycolic acid (MD Forte, Allergan) with either 0.05% tretinoin emollient cream (Renova,

Ortho Pharmaceuticals) or 10% L-ascorbic acid (SkinCeuticals) on a daily basis may slightly improve the appearance of striae alba.<sup>8</sup> In general, topical treatments have yielded disappointing results with only modest improvement reported in mature striae.

### LASER/ INTENSE PULSED LIGHT (IPL™) TREATMENT OF STRIAE

Many lasers including the CO<sub>2</sub>, Erbium:YAG, 1320 nm Nd:YAG and pulsed dye lasers have been used to treat scars and stretch marks.<sup>9,10</sup> Many have also used Intense Pulsed Light (IPL) with filters ranging from 550 nm to 590 nm, but no controlled trials have been performed. IPL induces some improvement of the erythematous component of new striae; however, the effects on mature striae are uncertain and have not been thoroughly studied.



**Handpiece for the ReLume system.**

## Contributing Authors

Pulsed dye laser therapy has been shown to improve all types of striae, but red, early striae improve more dramatically while white mature striae are less responsive. The optimal fluence was determined to be 3 J/cm<sup>2</sup> using a 10-mm spot size. This study also revealed that laser therapy of striae requires patience with continual improvement observed 6 to 12 months after treatment.<sup>11</sup> Using similar pulsed dye laser treatment methods, other investigators failed to note much clinical or histological improvement of striae.<sup>12,13</sup> The 1320 nm Nd:YAG dynamically cooled laser has been demonstrated to produce modest improvement (about 10% per treatment) in the texture of mature striae.<sup>14</sup> Therefore, lasers and light sources have not achieved consistent success nor has the mature hypopigmented component of striae been specifically addressed.

### LIGHT-BASED TREATMENT OF HYPOPIGMENTED SCARS

We have had initial success treating hypopigmented scars using the ReLume Repigmentation Phototherapy System, which combines the benefits of safe and effective UV phototherapy with the latest advances in targeted light technology.

Pilot clinical investigations with approximately 50 patients from our centers combined have shown repigmentation in approximately 80% of patients within a 2- to 3-month period, with a total number of treatments up to 14. Treatment fluences are initially administered at or slightly below the erythemogenic threshold and the dose is increased as patients become more photo-tolerant. The induction and retention of pigmentation varies somewhat and may depend on several factors including the individual's skin phototype, the body site treated and the type and age of the lesion. However, marked improvement is commonly observed beyond 3 months post treatment. These clinical trials are ongoing and the outcomes reported here represent very early clinical results.

Scars treated with this light source have varied from surgical incisions to the hypopigmentation seen as a late side effect of CO<sub>2</sub> laser resurfacing. Excimer laser phototherapy and topical photochemotherapy have also been used to provide moderately to highly effective repigmentation of laser resurfacing-induced leukoderma.<sup>15,16</sup>

An example of traumatic surgical scar repigmentation is shown in the photos on the previous page. This patient's scar acquired robust pigmentation in eight ReLume treatments, performed weekly to bi-weekly with a fluence of 260 mJ/cm<sup>2</sup>.

Treatment times are short, and coverage of large areas can be achieved quickly using a delivery spot of adjustable size and shape. A spacer on the handpiece allows the practitioner to visualize the treatment field to improve the accuracy of treatments.

### LIGHT-BASED TREATMENT OF MATURE HYPOPIGMENTED STRIAE ALBA

Striae assume their typical white sunken appearance in a

**Robert A. Weiss, M.D.** — Associate Professor of Dermatology, Johns Hopkins University School of Medicine

**Roy G. Geronemus, M.D.** — Director of the Laser & Skin Surgery Center of New York; Clinical Professor of Dermatology, New York University Medical Center, New York, NY

**Macrene Alexiades-Armenakas, M.D., Ph.D.** — Director of Research, Laser & Skin Surgery Center of New York

**Jeffrey S. Dover, M.D., F.R.C.P.C.** — Associate Clinical Professor of Dermatology, Section of Dermatologic Surgery and Oncology, Yale University School of Medicine; Adjunct Professor of Medicine (Dermatology), Dartmouth Medical School; Director, SkinCare Physicians of Chestnut Hill, MA

**Mitchel P. Goldman, M.D.** — Clinical Professor of Dermatology/Medicine, University of California, San Diego; Medical Director, Dermatology/Cosmetic Laser Associates of La Jolla

**Neil S. Sadick, M.D.** — Clinical Professor of Dermatology, Weill Medical College of Cornell University

**Christine C. Dierickx, M.D.** — Visiting Research Scientist, Harvard University Medical School; Consulting Staff, Department of Dermatology, University Hospital of Ghent, Belgium; Director of the Boom Laser Clinic, Belgium

**Jean Carruthers, M.D., F.R.C.S.(C), F.R.C.Ophth** — Clinical Professor, Department of Ophthalmology, University of British Columbia, Vancouver, Canada; Director, Carruthers Aesthetic Facial Ophthalmology

**Mark S. Nestor M.D., Ph.D.** — Clinical Associate Professor of Dermatology and Cutaneous Surgery, University of Miami School of Medicine; Director, The Center for Cosmetic Enhancement, Aventura, FL

**Darrell S. Rigel, M.D.** — Clinical Professor of Dermatology, Department of Dermatology, New York University School of Medicine, New York, NY

process very similar to that of surgical wound healing.<sup>5</sup> Based on the successful clinical trials of repigmentation of hypopigmented surgical scars, we believe that there is much promise in utilization of the ReLume device for selective repigmentation of mature striae alba. Initial clinical results have shown that the improvement of mature striae is possible with targeted UV phototherapy. Examples are shown in photos at right.

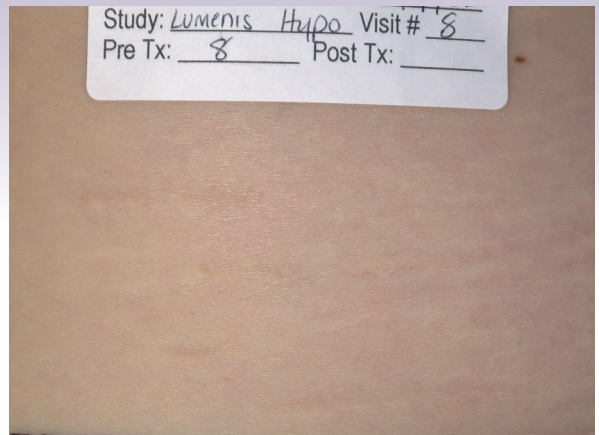
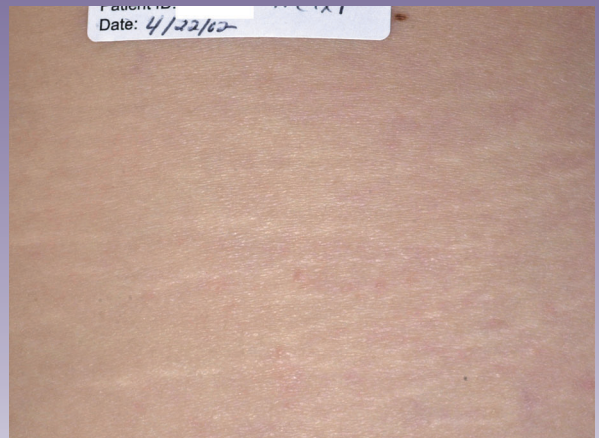
It is also interesting to speculate regarding the reversal of the atrophic nature of striae. The cutaneous responses to UV irradiation in human skin are well established. UVB irradiation results in epidermal hyperplasia and dramatic thickening of the stratum corneum.<sup>17,18</sup> Furthermore, UV irradiation can affect the arrangement of dermal matrix collagen and elastin proteins. This raises the possibility that targeted UV phototherapy administered with highly controlled doses will be able to treat both the depigmented and atrophic components of mature striae alba simultaneously. Ongoing clinical trials with histological evaluation will answer these questions.

## POSITIVE RESULTS

Striae are a very common cosmetic problem. There is great potential to improve the appearance by repigmentation of mature striae alba and hypopigmented white scars of multiple etiologies. Multicenter trials on hundreds of patients should be completed within the next year. The ReLume Repigmentation Phototherapy System appears to offer great promise. In preliminary clinical trials, excellent results have been observed with response rates as high as 80% in hypopigmented scars and mature striae alba. These results may be further enhanced in combination with other therapeutic modalities that aid in collagen remodeling in order to achieve safe and effective improvement in the appearance of mature striae distensae.

### References

1. Arnold HL, James WD, Odom RB. Abnormalities of dermal connective tissue. In: Odom RB, James WD, Berger TG, ed. *Andrews' diseases of the skin: Clinical Dermatology*. 9th edn. Philadelphia: W.B. Saunders Co., 2000: 645-646.
2. Lebwohl M, Ali S. Treatment of psoriasis. Part 1. Topical therapy and phototherapy. *J Am Acad Dermatol* 2001; 45:487-98.
3. Tsuji T, Sawabe M. Elastic fibers in striae distensae. *J Cutan Pathol* 1988; 15:215-22.
4. Sheu HM, Yu HS, Chang CH. Mast cell degranulation and elastolysis in the early stage of striae distensae. *J Cutan Pathol* 1991; 18:410-6.
5. McDaniel DH. Laser therapy of stretch marks. *Dermatol Clin* 2002; 20:67-76, viii.
6. Kang S, Kim KJ, Griffiths CE, et al. Topical tretinoin (retinoic acid) improves early stretch marks. *Arch Dermatol* 1996; 132:519-26.
7. Elson ML. Treatment of striae distensae with topical tretinoin. *J*



**Stretch marks on the right hip of a female patient before (top photo) and after (bottom) seven ReLume treatments. Total cumulative dose was 640 mJ/cm<sup>2</sup>.**

*Photos courtesy of Dr. Roy Geronemus & Dr. Macrene Alexiades-Armenakas*

*Dermatol Surg Oncol* 1990; 16:267-70.

8. Ash K, Lord J, Zukowski M, McDaniel DH. Comparison of topical therapy for striae alba (20% glycolic acid/0.05% tretinoin versus 20% glycolic acid/10% L-ascorbic acid). *Dermatol Surg* 1998; 24:849-56.
9. Alster TS, Lewis AB, Rosenbach A. Laser scar revision: comparison of CO<sub>2</sub> laser vaporization with and without simultaneous pulsed dye laser treatment. *Dermatol Surg* 1998; 24:1299-302.
10. Lupton JR, Alster TS. Laser scar revision. *Dermatol Clin* 2002; 20:55-65.
11. McDaniel DH, Ash K, Zukowski M. Treatment of stretch marks with the 585-nm flashlamp-pumped pulsed dye laser. *Dermatol Surg* 1996; 22:332-7.
12. Nehal KS, Lichtenstein DA, Kamino H, Levine VJ, Ashinoff R. Treatment of mature striae with the pulsed dye laser. *J Cutan Laser Ther* 1999; 1:41-4.
13. Nouri K, Romagosa R, Chartier T, Bowes L, Spencer JM. Comparison of the 585 nm pulse dye laser and the short pulsed CO<sub>2</sub> laser in the treatment of striae distensae in skin types IV and VI. *Dermatol Surg* 1999; 25:368-70.
14. Goldman MP, Rostan EF. Treatment of striae distensae with a 1320-nm dynamic cooling laser. *J Eur Acad Dermatol Venereol* 2000; 14(Suppl. 1):52.
15. Friedman PM, Geronemus RG. Use of the 308-nm excimer laser for postresurfacing leukoderma. *Arch Dermatol* 2001; 137:824-5.
16. Grimes PE, Bhawan J, Kim J, Chiu M, Lask G. Laser resurfacing-induced hypopigmentation: histologic alterations and repigmentation with topical photochemotherapy. *Dermatol Surg* 2001; 27:515-20.
17. Meischer G. Das problems des Lichtschutzes und der Lichtgewohnung. *Strahlentherapie* 1930; 35:403-43.
18. Rosario R, Mark GJ, Parrish JA, Mihm MC, Jr. Histological changes produced in skin by equally erythemogenic doses of UV-A, UV-B, UV-C and UV-A with psoralens. *Br J Dermatol* 1979; 101:299-308.





HMP COMMUNICATIONS

83 General Warren Blvd., Suite 100, Malvern, PA 19355

Phone: 800-237-7285 (610) 560-0500 Fax: 610-560-0501

[www.hmpcommunications.com](http://www.hmpcommunications.com)